



**PATIENT**

Hunter  
Bringhurst

**SPECIES**

Canine

**BREED**

Springer Spaniel

**SEX**

Male

**AGE**

10 years

**WEIGHT**

52.6lbs

**INTERPRETED BY**

Maggie Machen  
Lamy, DVM,

**IMAGING PERFORMED BY**

Loetitia St-Jacques,  
LVT/RVT

**HOSPITAL NAME**

Brighton Greens  
Veterinary  
Hospital

**REFERRING VET**

Dr.Janeway

**INVOICE**

22813

**DATE**

2/24/22

**PRESENTING CLINICAL SIGNS**

History: Grade 3/6 systolic murmur. Assess prior to dental.  
-Blood panel: PSL 144, USG 1.021, pro-1+, pH 8.5.

**ECHOCARDIOGRAM FINDINGS**

2D, m-mode, color flow and doppler imaging is available. Mild diffuse thickening of mitral valve leaflets with no prolapse into the left atrial lumen. Mild anterior-directed mitral regurgitation with no left atrial dilation. Normal LV diameter with adequate myocardial function. The tricuspid valve appears normal with trace tricuspid regurgitation. Normal velocity. Normal right atrial and ventricular diameter and morphology indicating no overt evidence of pulmonary arterial hypertension. The pulmonic and aortic valves are normal in morphology and mobility. Normal pulmonic and aortic outflow velocities with laminar flow. Dilated aortic root. No obvious aortic or pulmonic insufficiency. No pericardial or pleural effusion noted. No obvious cardiac masses.

**CARDIAC CHART**

| CANINE CARDIAC PARAMETERS   | MR VMAX (m/s) | TR VMAX (m/s) | LA/AO (Boon method) | LA/AO (Heart Base; Swe) | FS (%)                          | EF (%)                                   | EPSS (cm)                                |
|---|---------------|---------------|---------------------|-------------------------|---------------------------------|--|--|
| NORMAL PARAMETER  | 4.5-5.5       | <2.7          | 1.3                 | <1.6                    | 28-40                           | 40-100                                   | <0.6                                     |
| PATIENT   | NM            | 2.6           | NM                  | 0.9                     | 35                              | 65                                       | NM                                       |
| CANINE CARDIAC PARAMETERS   | HR (BPM)      | AV VMAX (m/s) | PV MAX (m/s)        | BODY WEIGHT (kg)        | LA 2D short axis Base view (cm) | LVIDd Avg; 2D and m-mode short axis (cm) | LVIDs Avg; 2D and m-mode short axis (cm) |
| NORMAL PARAMETER  | 50-100        | 0.7-1.7       | 0.7-1.6             | BELOW                   | BELOW                           | BELOW                                    | BELOW                                    |
| PATIENT   | NM            | 1.5           | 1.1                 | 23.9                    | 2.6                             | 3.4                                      | 2.2                                      |
| *Normal chamber parameters expressed as a mean value (SD)   |               |               |                     | 3                       | 1.27 (5.3)                      | 2.46 (2.46)                              | 1.36 (5.5)                               |
| <b>BODY WEIGHT DEPENDENT PARAMETERS</b>   |               |               |                     | 5                       | 1.40 (4.5)                      | 2.74 (5.2)                               | 1.60 (4.7)                               |
| <i>*Note: All measurements based upon multi-modal images and methods. An average value is reported.</i> |               |               |                     | 10                      | 1.50 (3.8)                      | 3.27 (3.5)                               | 2.06 (3.1)                               |
|   |               |               |                     | 15                      | 1.83 (2.0)                      | 3.71 (2.4)                               | 2.43 (2.1)                               |
|   |               |               |                     | 20                      | 2.02 (1.9)                      | 4.14 (2.2)                               | 2.80 (2.0)                               |
|   |               |               |                     | 25                      | 2.18 (2.4)                      | 4.48 (2.9)                               | 3.10 (2.5)                               |
|   |               |               |                     | 30                      | 2.33 (3.3)                      | 4.83 (3.9)                               | 3.39 (3.4)                               |
|   |               |               |                     | 35                      | 2.48 (4.3)                      | 5.17 (5.0)                               | 3.69 (4.5)                               |
|   |               |               |                     | 40                      | 2.62 (5.2)                      | 5.48 (6.1)                               | 3.96 (5.4)                               |
|   |               |               |                     | 50                      | 2.88 (7.1)                      | 6.07 (8.3)                               | 4.46 (7.4)                               |

Adapted from June Boon, Veterinary Echocardiography, 1998  
Rishniw M and Hollis NE, J Vet Intern Med 2000; 14:429-435  
Hansson et al, Vet Rad and Ultrasound 2002  
Bonagura et al. Echocardiography: principles of interpretation, Vet Clin North Am 15:1177, 1995

**INTERPRETATION OF THE FINDINGS & FURTHER RECOMMENDATIONS**

Chronic degenerative valve disease causing mild mitral and trace tricuspid regurgitation. Lack of significant left atrial enlargement indicates the current risk for complication is low. A dilated aortic is noted and a baseline blood pressure is recommended. No additional issues are identified.

In an asymptomatic dog with no significant left atrial enlargement, no cardiac medications are clearly indicated. Assessment of progression in the future will help predict long term prognosis, which is highly variable at this stage. Omega fatty acid supplementation and mild salt restriction may be of some long-term benefit. Monitor for development of a cough, labored breathing, exercise intolerance or collapse episodes.



**PATIENT**

Hunter  
Bringhurst

**SPECIES**

Canine

**BREED**

Springer Spaniel

**SEX**

Male

**AGE**

10 years

**WEIGHT**

52.6lbs

**INTERPRETED BY**

Maggie Machen  
Lamy, DVM,

**IMAGING PERFORMED BY**

Loetitia St-Jacques,  
LVT/RVT

**HOSPITAL NAME**

Brighton Greens  
Veterinary  
Hospital

**REFERRING VET**

Dr. Janeway

**INVOICE**

22813

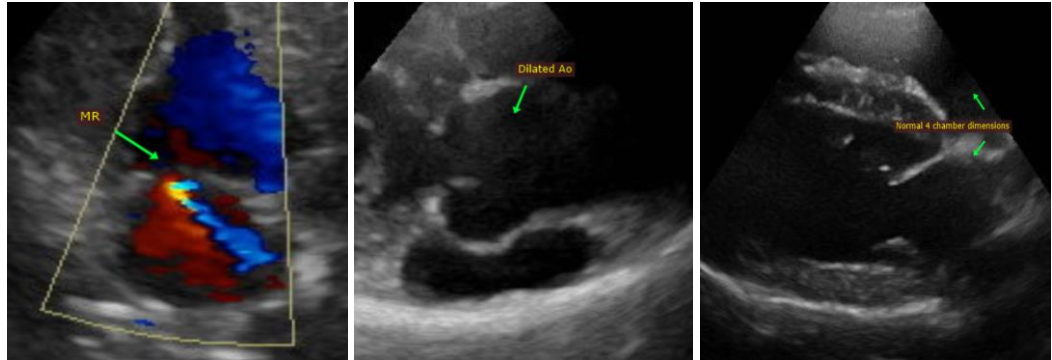
**DATE**

2/24/22

No cardiac contraindication for general anesthesia prior to chamber enlargement.

Recommend conservative monitoring with a recheck echocardiogram in 6-12 months, sooner if any development of clinical signs.

**IMAGES**



The information and recommendations provided are based on the images presented by the referring veterinarian. No evaluation can be communicated regarding pathology that was not visible in the image/video clips provided.

Thank you for this referral. This report was generated using transcription software, and minor dictation errors may be present. If the clinical or image interpretation does not parallel your findings or if I can be of any further assistance, please contact me.

**Maggie Machen Lamy, DVM**  
Diplomate of the American College of Veterinary Internal Medicine (Cardiology)  
info@sonopath.com